

PMCF Report, 19th June 2023

#OP6PC



Hydrolyzed Collagen 5mg/2ml

Medical device based on low molecular weight collagen peptides (LWPs). It is a ready-to-use injectable solution for the structural strengthening of connective tissues. Produced by Tiss'You.



Centro di medicina Villorba
Treviso, Italy

Paolo Donato Cortese



Paola Bortot



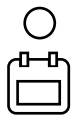
Rizoarthrosis
Grade 1-2



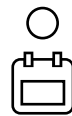15 patients
44-65 years



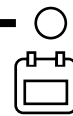**FIRST
TREATMENT**



1 MONTH



3 MONTHS



6 MONTHS

Background

Rizoarthrosis is a degenerative joint condition affecting the base of the thumb, characterized by cartilage deterioration, joint inflammation, and pain. Current treatment options for rizoarthrosis include nonsteroidal anti-inflammatory drugs (NSAIDs) for pain management, physiotherapy, and corticosteroid injections to reduce inflammation. However, these treatments often have limitations, such as temporary pain relief, potential side effects, and limited regenerative effects on the damaged joint tissues. To address these limitations, the rationale for using injectable hydrolyzed collagen peptides emerges. Collagen peptides, with their low mole-

cular weight and amino acid composition similar to native collagen, have shown potential in promoting tissue regeneration, cartilage protection, and reduction of pain and inflammation. As part of the treatment strategy, a static daytime brace is utilized post-collagen peptide administration. This brace serves to provide additional support and stability to the treated joint, immobilizing it during daily activities. By reducing joint movement and minimizing stress on the affected area, the brace complements the effects of collagen peptides, facilitating the healing process and enhancing overall therapeutic outcomes.



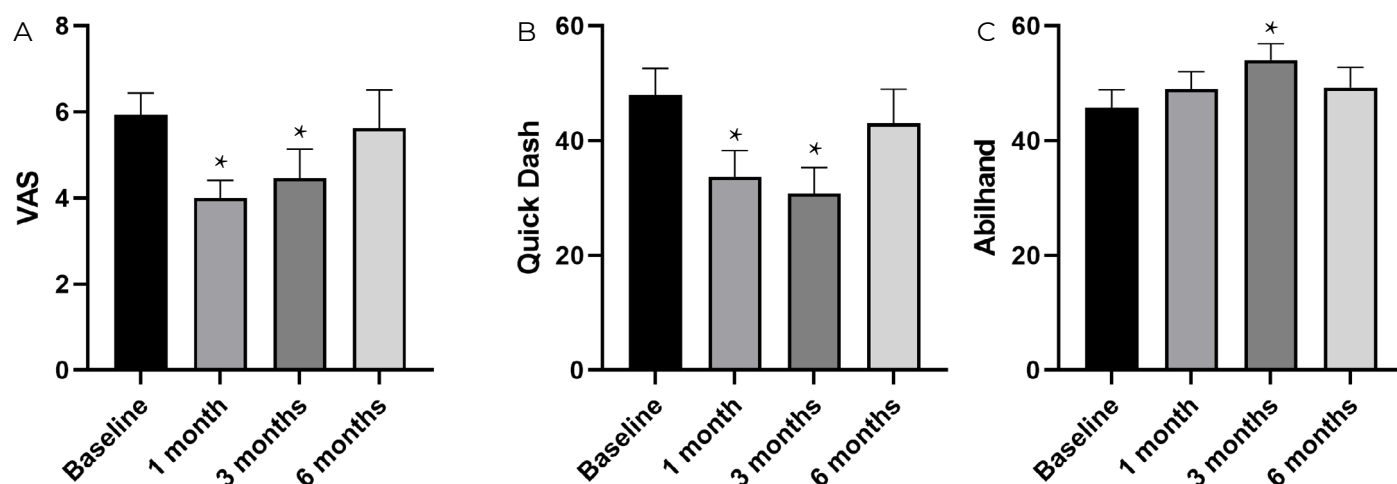
CHECK MORE ABOUT
HYDROLYZED COLLAGEN
PRODUCED BY TISS'YOU

Methods

Fifteen patients, aged 44 to 65 years, diagnosed with Rizoarthrosis (grades 1-2), received intra-articular injections of Low Molecular Weight Collagen Peptides (LWPs) targeting the Trapeziometacarpal (TMC) joint. Post-operatively, patients were provided with static daytime braces for management.

Patient assessments were conducted at specified intervals, including baseline, 1 month, 3 months, and 6 months. Pain levels were quantified using the Visual Analog Scale (VAS), while functional outcomes were measured using the Quick-DASH and Abilhand assessment tools.

Results



A. Mean Visual Analogue Pain, **B.** mean Quick-Dash score, **C.** mean Abilhand score (n=15) before and after Arthrys 5 mg/ml treatment. Secondary injection of Arthrys 5 mg/ml was performed at 6 months. Errors bars show SEM; *p < 0.01

Discussion

The findings demonstrated a notable decrease in the Visual Analog Scale (VAS) score (Fig. 1A), indicating reduced pain, with a 2-point drop observed at the 1-month follow-up. The pain relief remained satisfactory at the 3-month assessment; however, a slight resurgence of pain occurred at the 6-month mark, suggesting a relatively short-term effect of the treatment.

Regarding functional improvement, the QuickDASH score showed significant enhancement at both the 1-month and 3-month evaluations, indicating positive outcomes (Fig. 1B). However, by the 6-month evaluation, there was a recurrence of symptoms, indicating a partial loss of the initial functional gains. Similar patterns were observed in the Abilhand assessment (Fig. 1C), emphasizing the need for additional intervention to sustain the achieved im-

provements. Considering these findings, it is worth exploring strategies to optimize the long-term effects of the treatment. One potential approach could involve administering a second infiltration of hydrolyzed collagen peptides at either the 3-month or 6-month interval, aiming to reinforce and prolong the positive outcomes observed and potentially mitigate pain relapse and functional decline.

Throughout the study, no adverse events were reported, indicating that the hydrolyzed collagen peptide injections were well-tolerated. Only two minor complications associated with the treatment were reported, but they were easily resolved without recurrence. These results provide reassurance regarding the safety and tolerability of the treatment, supporting its potential as a viable therapeutic option for individuals with rizoarthrosis.